

**DATE PRESENTING CLINICAL SIGNS**

7.22.2022 Chronic inappetence, intermittent diarrhea.

**PATIENT**

Ginger Bromley

Current Medications: Ursodiol 150mg SID, Budesonide started 7/15/22, Metronidazole 375mg BID.  
 Lab Results: 7/7/22 AVIM appt- CBC: WBC 4.5K, lymphopenia 743. Chem: ALP 1151, UA (FC) 1.035, BP 180 systolic.

Date of Previous IntraPet Ultrasound: 11/26/21. See attached.

Sedation: Not required to complete full diagnostic ultrasound.

Stat Report: Not requested.

Imaging Performed By: Andi Parkinson, BS, RDMS.

**SPECIES**

Canine

**BREED**

Spaniel Mix

**SEX**

Spayed Female

**AGE**

12/14/2007

**WEIGHT**

41.1lbs

**ULTRASONOGRAPHIC EXAMINATION OF THE ABDOMEN****Urinary System**

The **urinary bladder** wall is normal in thickness and the mucosal surface is smooth. The bladder lumen is moderately distended with mostly anechoic urine. No masses, inflammatory changes or calculi are observed. Ureteral papillae and visualized portion of the proximal urethra, visible to a depth of 2 cm, are normal.

The **left kidney** is normal size (6.07 cm in length); normal shape and architecture with smooth peripheral margins. There is a normal 1:3 cortex to medulla ratio with mild to moderate loss of corticomedullary distinction. There is no evidence of pyelectasia, nephroliths, infarcts or hydroureter.

The **right kidney** is normal size (5.87 cm in length); normal shape and architecture with smooth peripheral margins. There is a normal 1:3 cortex to medulla ratio with mild loss of corticomedullary distinction. There is no evidence of pyelectasia, nephroliths, infarcts or hydroureter.

**Adrenal Glands**

The **left adrenal gland** is normal size (0.61 cm at cranial pole) (0.68 cm at caudal pole) (2.60 cm in length); normal shape; homogenous parenchyma. The glandular echogenicity and detail are unremarkable. Capsule, cortex, and medullary definition are normal. The phrenicoabdominal vein and surrounding vasculature are normal.

The **right adrenal gland** is normal size (0.74 cm at cranial pole) (0.63 cm at caudal pole) (2.65 cm in length); normal shape; homogenous parenchyma. The glandular echogenicity and detail are unremarkable. Capsule, cortex, and medullary definition are normal. The phrenicoabdominal vein and surrounding vasculature are normal.

**Spleen**

The **spleen** is normal in size (2.15 cm in width at the level of the hilus) with a normal capsular contour. There is appropriate echogenicity and echotexture. No focal lesions are observed. Splenic vasculature is normal.

**Liver**

The **liver** is subjectively enlarged with swollen peripheral contours. The parenchyma is isoechoic relative to the spleen and diffusely heterogenous in appearance. An approximately 3.80 cm heterogenous, cavitated vascular mass is observed deep on the left side. In addition, two 0.90 cm cysts are observed on the right. Hepatic vasculature and intrahepatic biliary tracts are of normal volume with no evidence of congestion.

The **gall bladder** lumen is moderately distended. The wall is thin and smooth. A moderate amount of echogenic to mineralized debris is observed within the lumen some of which is gravity dependent, and

**INTERPRETED BY**

Andrea Nicastro, DMV,  
 Diplomate DACVIM  
 (Small Animal  
 Internal Medicine)

**HOSPITAL NAME**

Timonium Animal  
 Hospital

**REFERRING VET**

Dr. McIntyre

**INVOICE**

11262

some of which is suspended. At least one distinct cholelith is also seen. The cystic and common bile ducts are normal/not seen.

### ***Gastrointestinal***

The **gastric lumen** is not distended. The gastric wall is normal in thickness with a normal layering pattern. The small intestinal lumen is not dilated. The small intestinal wall thickness is normal with a normal layering pattern and appropriate mural detail. Discreet masses are not identified. The colonic wall is normal. There is no evidence of an obstructive pattern.

### ***Pancreas***

The region of the **pancreas** is isoechoic relative to surrounding omental fat. No obvious parenchymal abnormalities are observed. There is no evidence of regional inflammation or effusion.

### ***Free Abdomen***

The **peritoneal cavity** is normal. There is no evidence of inflammation or effusion. The abdominal **lymph nodes** are normal/not visible.

## **ULTRASONOGRAPHIC FINDINGS**

### **Primary Findings**

- Hepatic mass, deep on the left side. Neoplasia (i.e., adenoma, adenocarcinoma, hemangiosarcoma, round cell tumor) is favored. However, a benign process (i.e., focus of regenerative nodular hyperplasia) cannot be completely excluded. The diffuse hepatic parenchymal changes trend toward the benign (i.e., nodular hyperplasia) with a lower possibility of infiltrative neoplasia.
- Gall bladder sand with at least one distinct cholelith, incidental

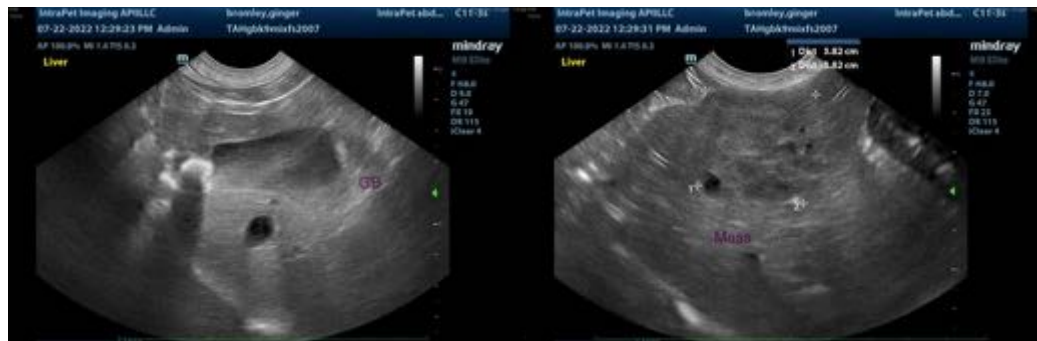
### **Secondary Findings**

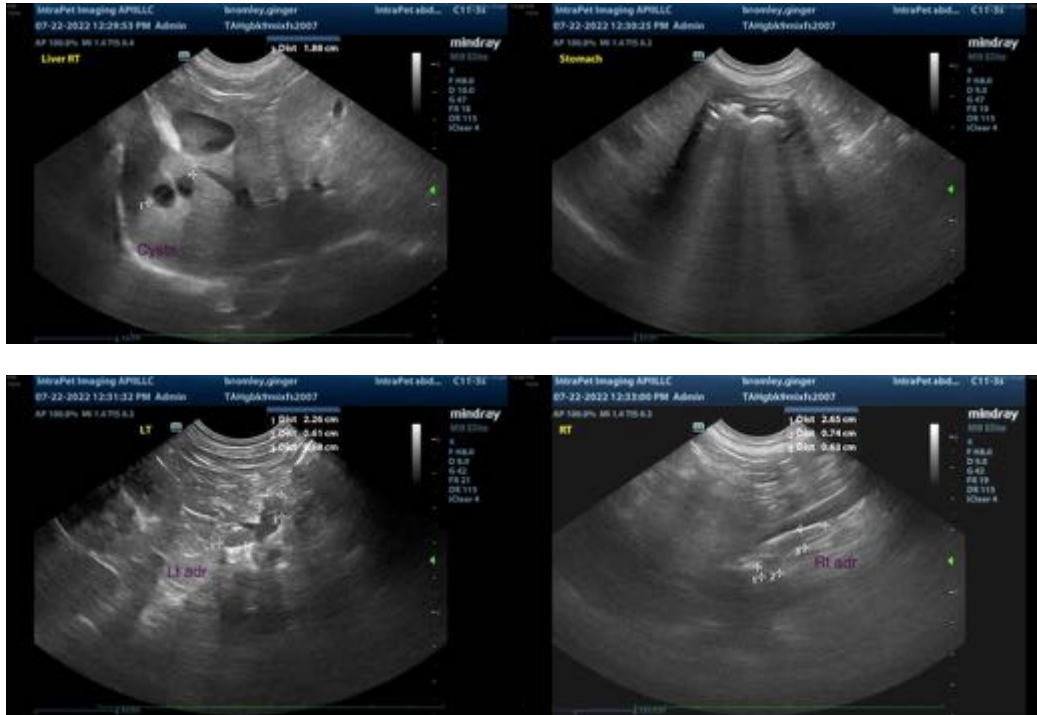
- Bilateral, chronic, age-related renal changes

## **INTERPRETATION OF THE FINDINGS & FURTHER RECOMMENDATIONS**

Three-view thoracic radiographs are recommended to assess for pulmonary metastases.

If an aggressive approach is desired, consider referral to a board-certified surgeon to discuss mass removal or debulking. An abdominal CT scan would be useful in presurgical planning. If surgery is not pursued at this time, palliative symptomatic care is recommended. A recheck ultrasound can also be considered in 6-8 weeks to assess for progression of the mass.





The information and recommendations provided are based on the images presented by the referring veterinarian/sonographer. No evaluation can be communicated regarding pathology that was not visible in the image/video clips provided.

Thank you for this referral. If the clinical or image interpretation does not parallel your findings or if I can be of any further assistance, please contact me.

**Andrea Nicastro, DVM, Diplomate DACVIM (Small Animal Internal Medicine)**  
info@SonoPath.com